



Compiled by Geoffrey M Knight

Minimal intervention cavity design

There is a perception that minimum intervention (MI) means cutting smaller holes in teeth. The aim of any MI procedure is to maximize the potential of a tooth to recover from either trauma or the effects of disease.

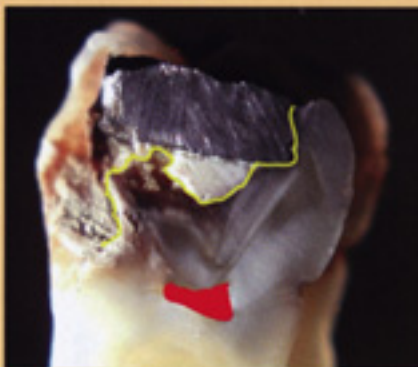


Fig 1. Extensive caries present under amalgam restoration.

GIC or resin bond linings for carious lesions

Figure 1 shows an extracted tooth with extensive caries under an existing amalgam restoration. The yellow line defines the boundaries of the tooth and pulp is shown in red.

The establishment of a marginal seal is an essential component in the restorative process. Marginal leakage may result in sensitivity and has the potentiality for recurrent caries.

Ralph Phillip's concept of preparing a moat around the lesion just within the dentine enamel junction assures sound dentine at the critical restorative interface and provides useful retention form at the periphery of the restoration. This is achieved using a #3 round bur.

Resin bond base

Cavity preparation for a resin bonded restoration requires removal of tooth structure until a sound dentine base has been achieved. In

a large lesion this may inadvertently lead to exposing the pulp. Figure 2 shows a carious tooth that has been prepared to remove all softened dentine.

Observe the dentine moat prepared around the perimeter of the preparation at the dentine enamel junction.

Importantly, the pulp has been exposed at the base of the cavity. Graham Craig points out that the consequences of a mechanical exposure such as this is equivalent to firing multiple fragments of infected dentine into the body of the pulp, resulting in a profound inflammatory response and jeopardizing pulpal vitality.

GIC base

Cavity preparation for a GIC base does not require the aggressive removal of softened dentine as

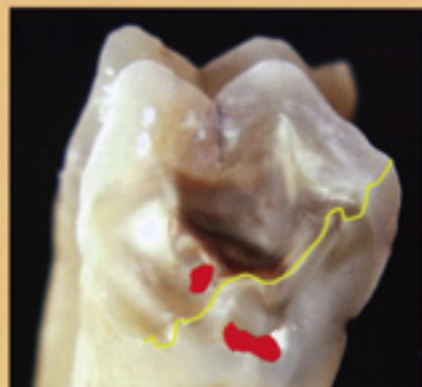


Fig 2. Resin bond preparation. Note caries exposure and peripheral dentine moat.

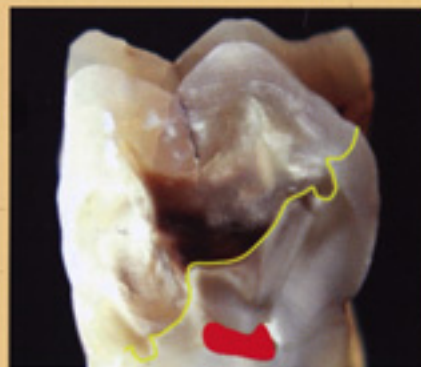


Fig 3. GIC preparation. Note peripheral moat and softened dentine on cavity floor.

required for resin bonding. While softened, non carious, affected dentine will remineralize, observations at the University of Adelaide suggest that even carious dentine will 'harden' under a GIC base as long as biological marginal seal has been achieved.

Figure 3 shows a cavity preparation for a GIC base. A dentine moat has been prepared to assure a peripheral seal and softened dentine has been left on the cavity floor, especially in the regions above the pulp. While this technique does not guarantee a non reactive tooth, the pulp tissue has a much greater chance of returning to health than if an exposure had occurred.

Cusp or occlusal overlays

Unprotected cusps in an extensive restoration are likely to fracture

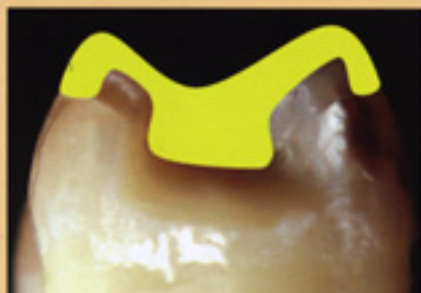

Fig 4. Cusp overlays require extensive tooth preparation and are difficult to contour.

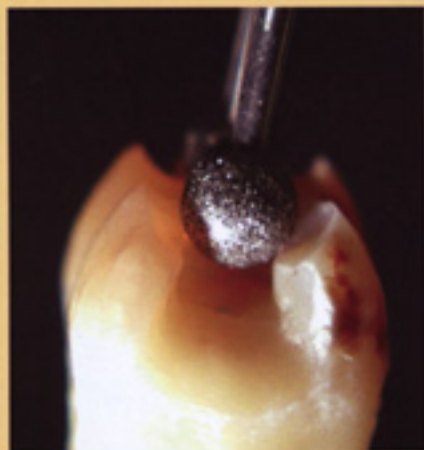


Fig 5. Occlusal overlay preparation using a high speed round diamond bur.

during the vigor's of mastication or parafunction.

Cusp overlays

Prior to adhesive dentistry, unsupported cusps were protected from fracturing using a cusp overlaying technique. This required removing cusp tips and finishing the preparation within the occlusal third of the perimeter of the tooth. Such

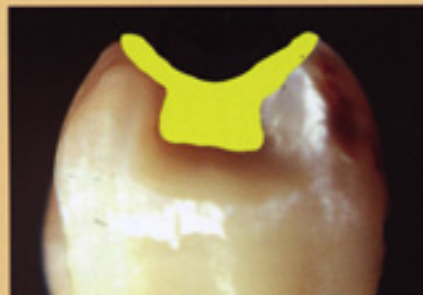

Fig 6. A conservative occlusal overlay restoration directs lateral forces back into the body of restoration.

preparations resulted in extensive removal of tooth structure (Fig 4).

These restorations are difficult to contour and often result in loss of cusp height and compromise of occlusal function.

Occlusal overlays

This technique has been promoted in Australia by Graham Mount for many years. Tooth preparation is much more conservative and can be rapidly achieved using a high speed diamond sphere (Fig 5). The slightly concave cavo enamel surface automatically bevel the margins and



Fig 7. A piece of freezer bag 3 cm square held with Miller's Tweezers makes a useful occlusal matrix.

provides greater bulk for composite resin at the restorative interface.

A tooth restored using the occlusal overlay technique protects the cusps by diverting occlusal forces back into the body of the restoration and is a much more conservative alternative to cusp overlaying (Fig 6).

Using an occlusal matrix, or freezer bag, in conjunction with the occlusal overlay preparation, excess composite can easily be trimmed using a 12 fluted TC bur and practitioners can rapidly create a restoration with a functional, contoured occlusal surface (Fig 7). □