



Compiled by Geoffrey M. Knight

Fishing line splints

The idea for this article belongs to John Mathieson of Bunbury Western Australia, obviously a keen angler, who came up with the concept of using fishing line as an alternative tooth splinting material.

General dentists see many patients with loose lower incisors caused by periodontal disease and bone loss. The majority of these patients, for a whole raft of reasons, wish to keep them for as long as possible.

There are a number of commercial fibres available for splinting and while most work successfully, John thought that fishing line may be a viable alternative. From the samples he forwarded, the **30 lb breaking strain, multi stranded Kevlar fishing line** seemed to work best. The yellow fibres were extremely strong, matched tooth colour and when impregnated with resin bonded well

to composite. This fishing line is freely available at tackle shops throughout Australia at a price that defies the cost of dental materials.

This patient had generalized bone loss around the lower incisors, especially 31 and 41 that were mobile to the degree where they interfered with mastication. The patient was aware of the hopeless

prognosis of these teeth but wished to retain them as long as possible. The clinical limitations of this splint were explained, pointing out that 31 and 41 were prone to developing abscesses at any time. It was further suggested that it may be possible to extend the clinical life of the splint by amputating the roots of these teeth if they caused problems, leaving the coronal portions as part of the prosthesis as shown in Fig. 1.

The six lower anterior teeth were prepared, using an end cutting flat fissure bur in a high speed hand-piece, by cutting a groove 1.5 mm in depth along the full length of the incisal edges of the lower incisors and two thirds along the incisal edges of the lower canines (Fig 2, Diagram 1). ▶

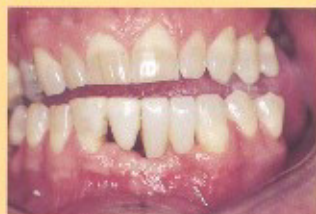

Fig. 1.

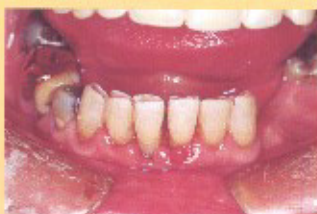

Fig. 2.

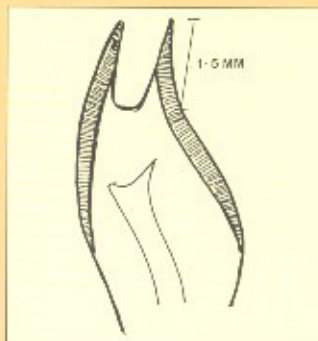


Diagram 1.



Fig. 3.

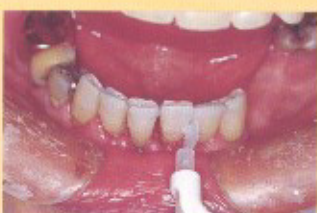

Fig. 4.

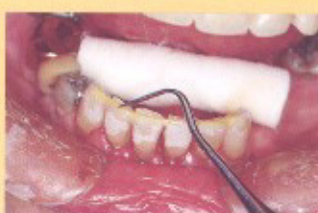

Fig. 5.

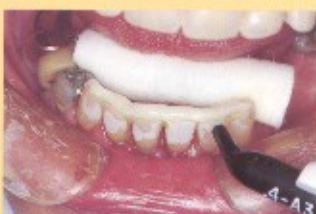

Fig. 6.

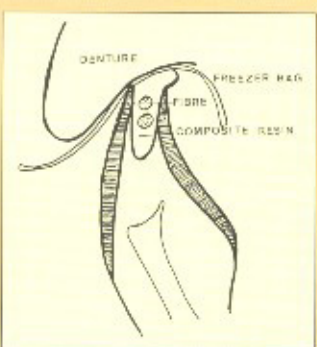


Diagram 2.

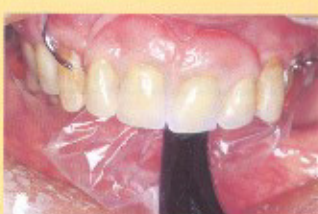

Fig. 7.

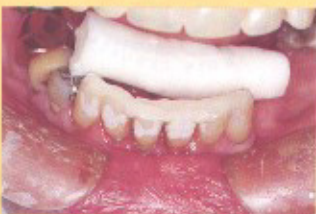

Fig. 8.

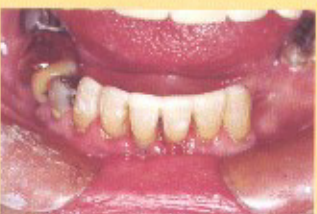

Fig. 9.

Two lengths of Kevlar fishing line were cut slightly longer than the length between the lower canines. The fibres were placed into the groove and trimmed so that they fitted snugly within the preparation.

The fibres were placed on a pad and impregnated with bonding resin (Fig. 3).

The teeth were etched with 37 per cent phosphoric acid for ten seconds, washed with water and thoroughly dried with oil free air (Fig. 4). ▶

After isolating the preparation with cotton rolls Fuji Bond LC* was painted thinly over the preparation and cured for 10 seconds.

After initial curing a further layer of Fuji Bond LC was painted over the surface and several small increments of Nulite F† were placed into the preparation to half fill the groove.

The impregnated fibres were next puddled into the uncured Nulite F using a perio probe or other suitable plastic instrument (Fig. 5).

Once the Kevlar fibres had been positioned into the groove a micro hybrid, Kerr Point 4‡ was injected over the fibres to fill the preparation (Fig. 6).

A freezer bag was placed over the uncured resin and the patient was asked to place the tongue at the back of the palate and to close firmly into centric occlusion (Diagram 2).

While the patients's teeth were closed, the restoration was cured for 10 seconds with the tip of the curing light positioned between the incisors (Fig. 7).

A further curing of 20 seconds with the teeth apart was then carried out.

Minimal contouring was required, as the splint had cured with the teeth in centric occlusion (Fig. 8).

Occlusal interferences were removed using coarse Sof-Lex discs and interproximal contouring was achieved with slow speed diamond points. Finishing was carried out with rubber wheels and fine Sof-Lex discs (Fig. 9).

Incorporating the fibres internally within the tooth makes the splint stronger and easier to tolerate. Grooves need to be prepared to a depth of 1.5 mm, as preparations less than this tend to fail. Irreversible tooth preparation has to be weighed against the doubtful prognosis if no intervention was undertaken. The general age of patients with advanced periodontal disease and sclerotic changes within the pulp usually mean there is a minimal chance of pulp exposure, although it is prudent to warn patients beforehand of this possibility. □

*G-C Japan - Halas Dental Pty Ltd, Waterloo NSW.

†Nulite Systems International Pty Ltd, Hornsby NSW.

‡Kerr Australia Pty Ltd, North Ryde NSW.