

Compiled by Geoffrey M. Knight

Minimally invasive restorative dentistry

The initiation and progression of dental caries has been observed and documented at a microscopic level for decades. Apart from the benefits of early application of topical fluorides and fissure sealing, the information gained from observing early caries has been poorly applied to clinical practice. This has been due to the absence of a predictable means of diagnosing early caries and secondly, a sufficiently conservative and accurate means of removing carious tissues without damaging healthy surrounding tooth structure.

The use of fissure sealing has been widely used as a conservative technique for managing potentially carious fissures on occlusal surfaces. When the technique was first introduced the caries incidence was substantially higher than today and routine fissure sealing of all occlusal

surfaces could be justified as a warranted preventive procedure. Current lower DMF recordings and the difficulties associated with diagnosing fissure caries has forced dentists into difficult decisions between overservicing and supervised neglect.

Caries diagnosis

The introduction of a reflected laser caries detector (Diagnodent)* has taken much of the stress out of occlusal caries diagnosis. The instrument consists of a laser beam surrounded by a glass rod that picks up the reflected light. Caries fluoresce at a different wavelength and the instrument gives a digital readout and an audio signal depending upon the reading. The deep growl it makes above 50 certainly tells patients that there is something seriously wrong in their mouths and that immediate attention is required.

Each instrument will give slightly different readings although a ►

*Ivoclar Pty Ltd, Noble Park, Vic.

calibrated instrument will consistently give the same reading. Clinical judgement is required to determine the level of intervention. The range of readings below is more conservative than that given in the manufacturer's instructions and may reflect the response of an individual instrument.

- A reading between 10-15 indicates early decalcification.
- A reading between 25-40 indicates early caries.
- A reading above 50 indicates an established carious lesion.

Prior to taking a reading the tooth should be dried and free from plaque and debris. False readings will be recorded if there is plaque or debris in fissures. The instrument responds unpredictably to composite resin, particularly at the cavo margins and readings must be weighed against the clinical appearance of the restoration.

The Diagnodent also has applications for diagnosing caries at crown and restorative margins and limited use for detecting proximal caries as the beam only penetrates about 2 mm into the tooth.

As readings from a calibrated instrument are reproducible, the Diagnodent can be used to monitor caries activity in a tooth over a period. Readings taken at one visit can be compared several months later to see if initial caries are increasing or responding to remineralization therapy.

Finally, during minimally invasive cavity preparation, the tooth simply has to be scanned to determine when caries have been removed, much faster and less messy than using a caries detector solution.

Caries removal

The air rotor established mechanical tooth cutting as an economical and efficient way to gain access and remove caries.

Over the years dentists have become used to hearing about lasers, ultrasonics, particle abrasion

and chemical dissolution being proposed as alternatives to mechanical tooth preparation and for numerous reasons, apart from particle abrasion, each option has failed to become commercially viable.

Particle abrasion, using small particles of aluminium oxide has emerged as a superior alternative to mechanical preparation when minimal cavity preparation is required.

High speed mechanical preparation requires constant cooling of the bur tip and therefore a significant amount of space is required around the bur to allow coolant access, resulting in the removal of healthy tooth tissue.

Furthermore, clinicians have limited control over positioning the cutting surface that inevitably results in over prepared flat floored cavity designs

that bear no similarity to the extent and position of the caries present.

During high speed mechanical tooth preparation, a slightly eccentric bur will set up vibrations that appear to cause micro fractures at the cavo margins, potentially weakening the cavo restorative interface.

Figure 1 shows a minimal intervention cavity prepared using a flat fissure diamond bur. A Diagnodent was used to establish that caries had been removed. After a resin restoration was placed the tooth structure was dissolved away showing the extent of tissue removal required (Fig. 2). Note the flat floored cavity design and the excess amount of healthy tooth structure that was required to prepare this cavity.

When a similar cavity was prepared using a Kreativ Mk5[†] air abrasion

[†]Dental Medical Technologies International Pty Ltd, Caulfield North, Vic.

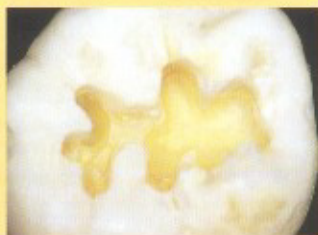

Fig. 1.

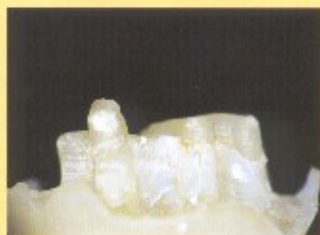

Fig. 2.



Fig. 3.

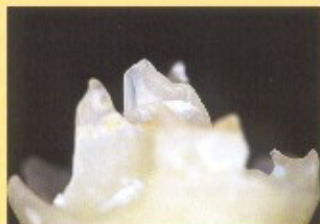


Fig. 4.